

# Mediterranean spotted fever and its complications in Mostaganem, Algeria

Bestaoui S <sup>2 \*</sup>, Amar NH <sup>2</sup>, Fellah M <sup>2</sup>, Bouhalloufa HF <sup>1</sup>, Adli F.Z. <sup>3</sup>

<sup>1</sup> Department of Medicine, University of Medicine Mostaganem, Algeria

<sup>2</sup> Department of Infectious Diseases, University of Medicine Mostaganem, Algeria

<sup>3</sup> Language Laboratory, University of Medicine Mostaganem, Algeria

\*Corresponding author E-mail: [samira.bestoui@univ-mosta.dz](mailto:samira.bestoui@univ-mosta.dz)

## Abstract

Mediterranean Spotted Fever (MSF) is an ancient anthroponosis of bacterial origin, in which the cause is *Rickettsia conorii* in which the vector of transmission to humans is the brown dog tick by bite. It is a seasonal disease raging in an endemic state in the Mediterranean region, including our region of Mostaganem (Western Algeria). It was a retrospective study based on the records of hospitalized patients at the infectious diseases department in Mostaganem, recording 36 cases of MSF, from 2023 to 2024. The majority of patients were male and had been in contact with dogs, both domestic and wild. In addition, the majority had a history of diabetes or hypertension and had taken antibiotics before hospitalization. Complications were, therefore, described in 12 of the 36 patients and were mainly nephrological, articular, cardiac, etc. The Direct Current (DC) of our patients was based on Raoult's diagnostic criteria given the endemic zone, because of the non-availability of serology, or the polymerase chain reaction (PCR) test. Although It remains a benign disease, it can be responsible for serious complications, whether reversible or not. It must be systematically evoked in the face of febrile eruptions during hot seasons in countries around the Mediterranean, including ours.

**Keywords:** Mediterranean Spotted Fever; *Rickettsia Conorii*; Rickettsiosis; Brown Dog Tick; Intracellular Bacteria.

## 1. Introduction

Mediterranean Spotted Fever (MSF) is an anthroponosis. It is the most common and frequent vector disease described, known as Mediterranean spotted fever. It is a bacterial infection caused by *Rickettsia conorii*, a small intracellular bacterium (considered to be a virus due to its size and mode of division by fission), transmitted to humans by the bite of the brown dog tick *Rhipicephalus sanguineus*, the vector and a reservoir of the disease[1]. It is the most common rickettsia endemic disease in the Mediterranean region (southern Europe and north Africa)[2], including Algeria, yet its exact incidence is not known due to the lack of reporting of this disease (often due to ignorance)[3]. It is a seasonal disease, occurring mainly in the hot, humid season. This season extended due to global warming and poor rainfall[4]. It is not contagious between humans and requires no isolation measures. It is one of the infectious endothelitis[5] due to antigen-antibody deposition at different endothelial sites (renal, cardiac, nervous, articular, ocular, hepatic, and others), leading to platelet abnormalities ranging from benign to true disseminated intravascular coagulation (DIC); which explains the clinical manifestations[6].

It is a condition with a reputation for being falsely benign, in fact, it can develop favorably even spontaneously, but complications are frequent (6-7%) and can be fatal (fatality 2-5%) if they are not treated quickly[7]. The clinical display, along with a robust epidemiological nature of the bacteria[10] and is still not useful for initiating rickettsia-specific treatment with doxycycline 200 mg/d for all forms of the disease. Early initiation of treatment is crucial for the proper course of the disease since it should be noted that the use of non-rickettsia antibiotics, such as lactam antibiotics, may be a risk factor for complications [11]. Mortality is considered to be rare, but possible in the case of MSF [12].

Biological tests often show hyperleukocytosis with inflammatory syndrome, moderate thrombocytopenia with high DC, and discrete cytotoxicity syndrome. Microbiological, serological, or PCR confirmation is not common as bacterial culture is hard due to the intracellular nature of the bacteria[10] and is still not useful for initiating rickettsia-specific treatment with doxycycline 200 mg/d for all forms of the disease. Early initiation of treatment is crucial for the proper course of the disease since it should be noted that the use of non-rickettsia antibiotics, such as lactam antibiotics, may be a risk factor for complications [11]. Mortality is considered to be rare, but possible in the case of MSF [12].

MSF prophylaxis is crucial in certain specific situations (profession, hiking); although not 100% effective [13], it primarily consists of avoiding contact with the brown dog tick and its bite. Contact acaricides, wearing long clothing, and treatment of dog ticks are necessary steps for prevention [14]. This study's objective is to determine the pathology's frequency in the Mostaganem region of western Algeria, the frequency of complications' transitions, and their types.

## 2. Methodology

### 1) Study Concept

This is a retrospective descriptive study of patient profiles that were hospitalized at the infectious illnesses department in Mostaganem, Algeria. The study duration is two years, from May 2022 to October 2024.

### 2) Study Population

The study was carried out at the Mostaganem University Hospital on patients over 15 years old. These patients were hospitalized within the Infectious Disease Department for the management of an eruptive acute fever, regardless of the complications, as the Raoult's epidemic and biological diagnostic criteria puts it. The serological diagnosis was not realized for all patients. Also, patients with a benign form of the disease were hospitalized to monitor the occurrence of a possible late complication.

### 3) The Inclusion Criteria

This study included 36 patients over 15 years old visiting for a consultation or oriented by another specialty doctor for an eruptive fever, who met the Raoult diagnostic criteria of the MSF, regardless of sex. In addition, this investigation included the patients who started an external antibiotic treatment and pursued their clinical diagnosis at our level.

### 4) The Progress of the Study

The data collection was carried out using the medical profiles of hospitalized patients in the University Hospital Center (UHC) of Mostaganem (Algeria) at the Infectious Diseases Department. These records were carefully realized by the creation of a questionnaire that included various diagnostic criteria from an epidemiological, clinical, and biological perspective.

### 5) Data Analysis

Data entry, treatment, and analysis were performed by SPSS software: version 23 and MS Excel. The software dealt with statistical analysis, comparing data to inclusion, and correlations between variables. The data were collected over two years, 2022 to 2024. These data included age, sex, occupation, history, the notion of contact with dogs, the concept of consultations before hospitalization, the clinical state to admission, the initial biological assessment, signs of admission complication, the appearance of late complications, antibiotic treatment, duration of hospitalization, having an appeal to other specialties for their medical care.

## 3. Results

The study included 36 patients with MSF pathology. The epidemiological presentation was that male sex accounted for 75% of cases. The social status was predominantly unemployed (n = 15), farmer (n = 13), a housewife (n = 3), an employee (n = 3), and a student (n = 2). The average age of patients was 38.3 years old, with extremes of 17 and 78 years old; 64.7% reported contact with dogs, whether domestic or wild (n = 8). The rural origin of the patients was found in 28 cases.

The patients' histories were mainly represented by diabetes (n = 9), in which 4 were inaugural, as well as high blood pressure with or without other anomalies (n = 14); 11 patients were without particular history. The occurrence of the MSF was predominant in June and August (27.78% each). The distribution is shown in graph N ° 1. Clinically: the fever was constant with variability, it exceeded 38.7 ° in 72.2% of cases (n = 26). The eruption was generalized maculopapular in 63.9%; Table 1 shows the others. The inoculation eschar (black spot) was present in the majority of the cases in which 80%. It was double in 3 patients, the location of the latter is shown in Table 2. The adenopathy was present in 30% of cases. They were mostly satellites with inoculation chancre. The chancre was replaced by unilateral conjunctivitis in 3 patients. The complications were observed in 33.3% of cases, as illustrated in Graph 2. 20 patients took antibiotics before their hospitalization, 8 of them had developed complications.

**Table 1:** Type of eruption

Eruption	Frequency	Percentage
Maculopapular	23	63,9
Purpuric	4	11,1
Atypical	5	13,9
Attenuated	4	11,1

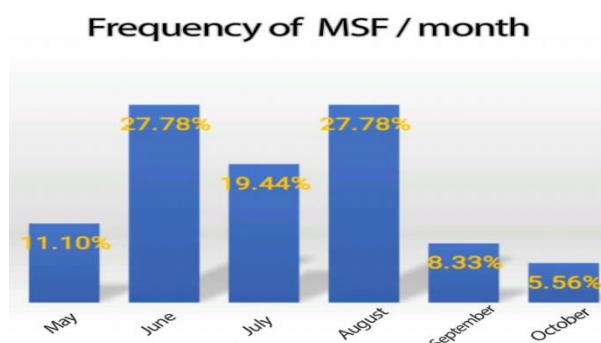
**Table 2:** Location of inoculation chancre

Eschar	Frequency	Percentage
Axillary	11	30,6
Inguinal	6	16,7
Ear or scalp	3	8,3
Exposed areas of the body	9	25,0
Not found	7	19,4

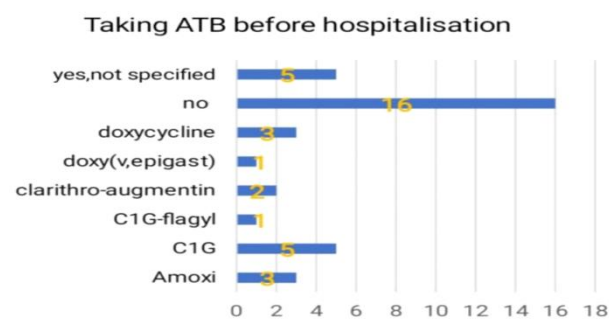
Complications occurrence was initial at the same time as hospitalization in 6 patients (16,6% of cases). It was a neurological involvement in two cases (convulsion, pure liquid meningitis), nephrological in one case, hematological in one case, and one liver case. The rest of the complications were undertaken during the hospitalization thanks to an ECG discovering myocarditis, two aseptic joint damages of the knee, and anuria. A resuscitation transfer was necessary before the neurological complication in which 2 out of 4 patients benefited from several dialysis sessions before retrieving their renal function entirely. No deaths have been explored in our series of studies.

On the biological level, the totality of the patients had neutrophilic polynucleotide hyperleukocytosis, half of the cases either (n = 18) had thrombocytopenia  $m < 110000$  elements/mm<sup>3</sup>, of which four patients required a transfusion of one / or more cups ( $< 250000$  elements/mm<sup>3</sup>). Cytolysis syndrome was discovered in 73% of patients. It was most often discreet and did not exceed the double of the standard rate. One hypoalbuminemia and one collapsed TP at 45% were considered hepatic involvement. In this study, no specific serology has been carried out (not available) or PCR (cost and time).

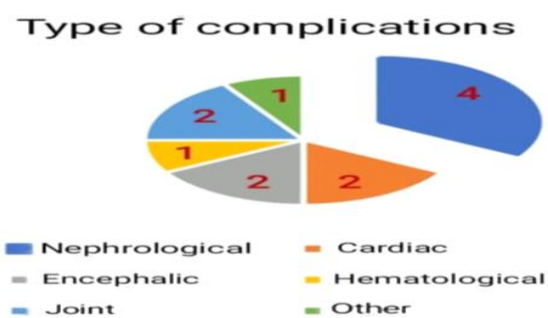
Treatment was based on doxycycline 200 mg/day in 30 patients. The six other patients received a Ciprofloxacin 400 or 800 mg / j based on the clearance of creatinine. The switch to ciprofloxacin was justified by the impossibility of swallowing and non-availability of injectable cyclins. Corticosteroid therapy was used in 29% of cases and was essentially second-line, based on prednisolone 1 mg/kg/day for 3 to 5 days, used mainly in myocardial, encephalic, and aseptic articular.



Graph 1: Frequency of Occurrence of MSF/Month.



Graph 2: Antibiotics Before Hospitalization.



Graph. 3: Complications (Headcount).

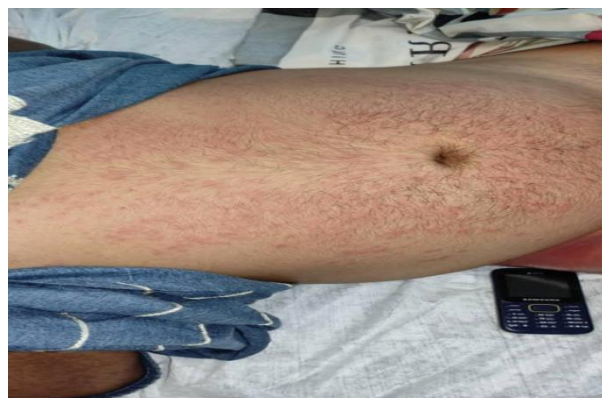

Photo. 1: Maculopapular Eruption.

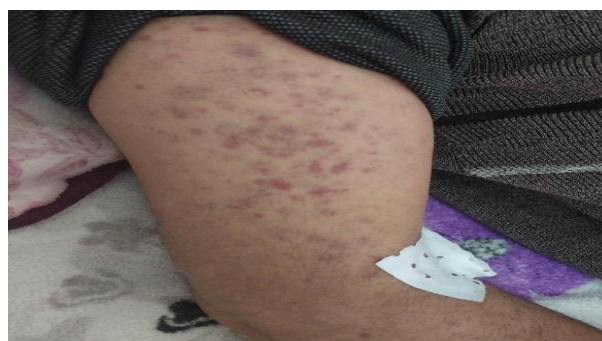
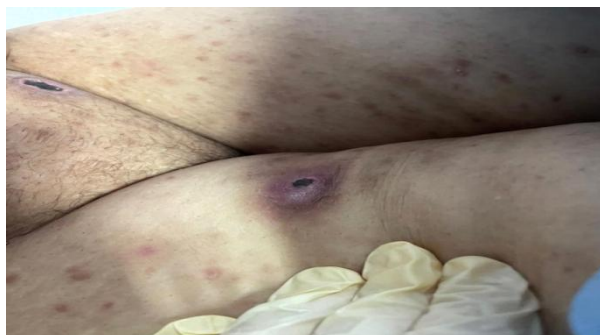
Photo. 2: Purpuric Eruption.



**Photo. 3:** Tick on A Patient.



**Photo. 4:** Complicated Double Canker.

## 4. Discussion

MSF is an old bacterial disease described as an epidemic with a Mediterranean circumference at a prevalence of 12 to 20% [15]. The authors are unanimous on the age of occurrence and the epidemiological modalities. Although it evolves in a dozen days, complications can occur and are a crucial challenge. It would be responsible for severe visceral forms in 10 to 20% of cases [16]. our study reports more or less the same figure with 16,6% of all that complicates.

Kidney damages were the most common complications in our investigation, which aligns with several publications (the case of Ibrahim Mountassers D et al. and Skhiri et al) [17]. The authors diverge on the mechanism of occurrence of the latter. The reversible aspect in our series means that the damage was more apparent at the level of the function rather than the lesion. Consequently, a late diagnosis can expose the transition to irreversible tubular necrosis. Mortality in this situation increases considerably to 32.3% (Portugal) [2].

Neurological damages are variable and can range from simple confusion to a distinct encephalic case and even to meningoencephalitis. Pure meningitis is the most frequently described. Brain vascular damage, Guillain- Barré syndrome, myelitis, or others are also possible probabilities [18]. This study revealed that both brain damages presented meningeal participation, which aligns with the literature.

**Table 3:** Description of Neurological Damage in the Literature [19 - 22]

Study	Year	Types of neurological complications	Detection methods	Confirmation
Hammami et al.	2021	Lymphocytic meningitis (87.1%), meningoencephalitis (12.9%),	Lumbar puncture showing lymphocytic pleocytosis.	Diagnosis confirmed by serology
Boulahri et al.	2017	Ischemic cerebrovascular accident (cerebral infarction),	Cerebral angio-MRI showing deep left sylvian infarction.	Dc Score
Hsaini et al.	2017	Meningoencephalitis, peripheral facial paralysis, Guillain-Barré syndrome,	Cerebral Imagery	Serology confirming Rickettsia conorii infection.
Smaoui et al.	2014	Meningitis (50%), encephalitis (25%), meningoencephalitis (15%), cerebritis (5%), facial paralysis (5%),	Lumbar puncture with pleocytosis and standard chemistry	Positive serology for Rickettsia conorii in 35% of patients.
Berrich et al.	2006-2017	Meningoencephalitis, cerebellar ataxia, Miller-Fisher syndrome	Imagery	Rickettsia conorii specific serology and polymerase chain reaction (PCR)

Joint damages make the clinical diagnosis of this pathology very particular. They vary from a simple initial symptom resulting in diffuse and intense arthralgia to going beyond this description to mimic a real complication, to be often simulated with other rheumatic or abuses, thus, complicating diagnosis and treatment (Sargsyan et al.) [23]. This detailed limit requires a good understanding of the pathophysiology of the MSF in the area of bacterial invasion of the articular synovial or a strong local inflammatory response to this process inducing the deposit of immune complexes antigen-antibody, explaining the pain and joint swelling at different levels. It remains to be said that these disorders are quite common in elderly subjects with a predisposition to joint damage [24]. It was not the case in our study, where the damage occurred in two middle-aged women. This understanding will mainly guide the demand for complementary examinations on the joints "Springer Science and Business Media LLC" but also the conduct of antibiotic therapy and the need to administer anti-inflammatory drugs (corticoid therapy) to act against the continuous inflammatory process and against the pain. This particular complication turned MSF from the case of a benign severe disease to a prolonged time disease, as well as increased the duration of hospitalization of our two patients by more than 10 days, which was the case in the literature [25].

Cardiac damage of the MSF, in which their cause was essentially immunological, worsens the situation. They often appear few days after the symptoms and are variable. However, the most described is myocarditis, in which the evolution is unpredictable and can be reversible [26]. According to this study, the myocarditis results were aligned with the literature's findings.

**Table 4:** Myocardial Damage in the Literature [27 - 30]

Study	Year of the Study	Authors	Results
"Complications of Mediterranean spotted fever"	2002	Bellissima P, et al.	Myocarditis accounted for 12.7% of the 525 cases of MSF
"Fatal invasive rickettsiosis diagnosed late in the resuscitation"	2017	Ghezala HB, et al.	Presentation of a fatal case of MSF following a cardiac complication
"A severe myocarditis complicating a Mediterranean spotted fever".	2012	Ben Mansour N, et al.	Severe case of MSF with myocardial complication
"Clinical approach to rickettsioses".	2007	Parolla P, et al.	Complications during MSF at 10% including myocarditis with a mortality rate of 4%.

Other complications are possible, such as ocular damage (of simple conjunctivitis to conjunctival hemorrhage, uveitis, corneal abscess, keratitis, etc.) [31] and hematological damage (especially the intravascular coagulation disseminated IVCD).

In our investigation, the certainty DC is lacked of laboratory results is namely serology and/or PCR, however, many care centers also base their work on the same DC protocol (the nonspecific Raoult Epidemioclinical and Organic Score).

Criteria	Points
<b>Epidemiological Criteria</b>	
Living or staying in an endemic area	2
Occurring between May and October	2
Certain or probable contact with dog ticks	2
<b>Clinical criteria</b>	
Fever over 39°	5
Eschar	5
Maculopapular or purpuric	5
Two of the above criteria	3
The three previous criteria	5
<b>Non-specific biological criteria</b>	
Platelets <150 GL-1	1
SGOT or SGTP >50 IUL-1	1
<b>Bacteriological criteria</b>	
Blood isolation	25
Detection on a skin biopsy	25
<b>Serological criteria</b>	
Single serum and IgG >1/128	5
Single serum, IgG >1/128 and IgM >1/64	10
Variation of 4 dilutions of the rate between 2 years	25

**Fig. 1:** Raoult's Dc score.**Table 5:** Studies using the Raoult score [32 - 34]

Study	Year of the Study	Raoult Score (>25)	Complementary methods
Mediterranean Spotted Fever: Current Knowledge and Recent Insights	2021	Confirmed use as a primary tool for clinical diagnosis	No explicit use of serology or PCR, diagnosis based on clinical criteria
Mediterranean Spotted Fever in Southeastern Romania	2013	50.4% of cases had a score >25	Epidemiological and clinical assessment
Button fever Mediterranean in Tlemcen	2016	Bouabdellah A, et al.	Non-specific epidemiological and clinical evaluation

The basic treatment was doxycycline 200 mg/d for our patients, except where the oral route was impossible, ciprofloxacin would replace the latter, in which the case in the literature [35]. Other studies were against this practice given the deleterious risk of ciprofloxacin [36].

## 5. Conclusion

Mediterranean spotted fever is an example of zoonosis in which a domestic animal is the immune carrier of the disease. Always deemed to be benign, even staying unknown, the MSF remains one of the most frequent infections via consultation in the endemic area. It is also frequent in the hot season and always requires reflection by the doctors, specifically when it appears in its atypical form, or when associated with one or more complications. Doctors need to review the basics of Mediterranean spotted fever, especially in patients suffering from an associated defect, because it often causes significantly underestimated morbid mortality. The insistence on achieving a definitive bacteriological diagnosis and/or immunohistochemical certainty should not be slow to start treatment and systematic research of a complication. The misuse of certain antibiotics (especially lactams) can be negative in terms of MSF.

## 6. Limits of the study

- Absence of a witness group.
- Modest sample size.
- Selection bias is possible.
- Diagnosis was realized only by the Raoult DC score.

## 7. Conflict of interest

The authors declare no conflict of interest.

## References

- [1] Psaroulaki A · Germanakis A · Gikas A . Premier isolement et identification génotypique de *Rickettsia conorii* Malish 7 chez un patient en Grèce. *Eur J Clin Microbiol Infect Dis*. 2005; 24:297-298 <https://doi.org/10.1007/s10096-005-1304-z>.
- [2] De Sousa R., Nobrega S. D., Bacellar F., and Torgal J. Mediterranean spotted fever in Portugal: risk factors for fatal outcome in 105 hospitalized patients, *Annals of the New York Academy of Sciences*. (2003) 990, 285–294, 2-s2.0-0038390985. <https://doi.org/10.1111/j.1749-6632.2003.tb07378.x>.
- [3] Bouchaib H. et al. Tick-and flea-borne rickettsioses in Tizi-Ouzou, Algeria: Implications for travel medicine, *Travel Med Infect Dis* (2018)] Mouffok N. et al. Mediterranean spotted fever in Algeria--new trends. *Int J Infect Dis* (2009) <https://doi.org/10.1016/j.tmaid.2018.11.005>.
- [4] Socolovschi C. et al. Influence of temperature on the attachment of *Rhipicephalus sanguineus* ticks on rabbits. *Clin Microbiol Infect* (2009) <https://doi.org/10.1111/j.1469-0691.2008.02260.x>.
- [5] La Scola B, Raoult D - Laboratory diagnosis of rickettsioses: current approaches to diagnosis of old and new rickettsial diseases. *J Clin Microbiol* 1997 ; 35 : 2715-2227. <https://doi.org/10.1128/jcm.35.11.2715-2727.1997>.
- [6] Vitaliti G, Falsaperla R, Lubrano R, Rapisarda V, Cocuzza S, Nunnari G, Pavone P. Incidence de la fièvre pourprée méditerranéenne chez les enfants siciliens : une étude rétrospective observationnelle clinico-épidémiologique de 1987 à 2010. *Revue internationale des maladies infectieuses*. Volume 31, février 2015, pages 35-40. <https://doi.org/10.1016/j.ijid.2014.11.001>.
- [7] Anton E, Font B, Munoz T, Clinical and laboratory characteristics of 144 patients with Mediterranean spotted fever. *Eur J Clin Microbiol Infect Dis* 2003;22:126–8. <https://doi.org/10.1007/s10096-002-0879-x>.
- [8] Caisso C. et al. A case of uveitis due to *Rickettsia conorii* infection in Southeastern France *Ticks Tick Borne Dis*. (2016)] Parola P, Eldin C. La fièvre boutonneuse méditerranéenne : actualités *The Mediterranean*. Spotted fever: actuality. *Revue Francophone des Laboratoires*. Volume 2019, Issue 513, June 2019, Pages 55-60. [https://doi.org/10.1016/S1773-035X\(19\)30289-8](https://doi.org/10.1016/S1773-035X(19)30289-8).
- [9] Bousser M G, Mas JL. Accidents vasculaires cérébraux. *Lancet Neurol*. 2009; 8:643-653.
- [10] Eldin C. et al. Limitations of diagnostic tests for bacterial infections. *Med Mal Infect* (2019). <https://doi.org/10.1016/j.medmal.2018.12.004>.
- [11] Parola P, Eldin C. La fièvre boutonneuse méditerranéenne : actualités *The Mediterranean*. Spotted fever: actuality. *Revue Francophone des Laboratoires*. Volume 2019, Issue 513, June 2019, Pages 55-60. [https://doi.org/10.1016/S1773-035X\(19\)30289-8](https://doi.org/10.1016/S1773-035X(19)30289-8).
- [12] Papa A, Dallab V, Petalac A, Maltezoud H.C, Maltezos E. Fatal Mediterranean spotted fever in Greece. *Bacteriology* Volume 16, Issue 6p589-592 June 2010. <https://doi.org/10.1111/j.1469-0691.2009.02910.x>.
- [13] Kleine-Tebbe J, Heinatz A, Gräser I, Dautel H, Hansen GN, Kespohl S, Rihs HP, Raulf-Heimsoth M, Vater G, Rytter M, Hausteil UF. Bites of the European pigeon tick (*Argas reflexus*): Risk of IgE-mediated sensitizations and anaphylactic reactions. *J Allergy Clin Immunol*. 2006 Jan;117(1):190-5. <https://doi.org/10.1016/j.jaci.2005.08.056>.
- [14] Boulanger N, Lipsker D. Protection contre les piqûres de tiques Protection against tick bites. Volume 142, Issue 4, April 2015, Pages 245-251. *Annales de Dermatologie et de Vénéréologie*. <https://doi.org/10.1016/j.annder.2014.11.018>.
- [15] Ibrahim Montasser D, Zajjari Y, Alayoud A, Bahadi A, Aatif A, Hassani K, Hamzi A, Allam M. Acute renal failure as a complication of Mediterranean spotted fever. *Néphrologie et Thérapeutique*. Volume 7, Issue 4, July 2011, Pages 245-247. <https://doi.org/10.1016/j.nephro.2011.02.002>.
- [16] Raoult D et al. Rickettsioses as paradigms of new or emerging infectious diseases. *Clin Microbiol Rev* 1997. <https://doi.org/10.1128/CMR.10.4.694>.
- [17] Skhiri H, Zellama D, Aloui S, Bouraoui S, Frih MA, Achour A, Ben Dhia N, ElMay M. Insuffisance rénale aiguë au cours de la fièvre boutonneuse méditerranéenne : description de trois observations. *Med Tropicale*, 2004, Vol 64, Num 1, pp 58-60.
- [18] Thèse : "La fièvre boutonneuse méditerranéenne à Tlemcen". Université de Tlemcen, 2021 : <https://dspace.univ-tlemcen.dz/bitstream/112/9423/1/Fievre-Boutonneuse-Mediterranee-a-Tlemcen>.
- [19] Hammami F, Koubaa M, Chakroun A, Smaoui F, Marrakchi C, Rekik K, Ben Jemaa M. Forme neurologique de la fièvre boutonneuse méditerranéenne. *Rev Neurol (Paris)*. 2021;177(5):472-478. *Revue Neurologique* 2021. <https://doi.org/10.1016/j.neurol.2021.02.235>.
- [20] Boulahri T, Taous A, Aït Berri M, Traïbi I, Elbenaye J, Rouimi A. Infarctus cérébral révélant une fièvre boutonneuse méditerranéenne. *Pan Afr Med J*. 2017;26:80. <https://doi.org/10.11604/pamj.2017.26.80.11434>.
- [21] Hsaini Y, Mounach J, Zerhouni H, Satté A, Mosseddaq R. Complications neurologiques de la fièvre boutonneuse méditerranéenne : à propos de cas. *Rev Neurol (Paris)*. 2017;173(Suppl 1):A12.
- [22] Berriche A, Ammari L, Abdelmalek R, Kanoun F, Ghoubontini A, Kilani B, Tiouiri Benaissa H. Complications neurologiques au cours de la fièvre boutonneuse méditerranéenne. *Rev Neurol (Paris)*. 2014;170(Suppl 1):A30. [https://doi.org/10.1016/S0399-077X\(14\)70186-6](https://doi.org/10.1016/S0399-077X(14)70186-6).
- [23] Sargsyan A, "Essential Notes on Pathophysiology for Advanced Practice Nurses", Digital Commons @ East Tennessee State University, 2020.
- [24] Gospodinova M, Nenova M, "Mediterranean Spotted Fever in Adults Aged Over 60 Years", 'Medical University Prof. Dr. Paraskev Stoyanov - Varna', 2003.
- [25] "Skills in Rheumatology", 'Springer Science and Business Media LLC', 2021.
- [26] Nilsson K, Lindquist O, Pahlson. Association of *Rickettsia helvetica* with chronic perimyocarditis in sudden cardiac death. *Lancet* 1999;354:1169–73. [https://doi.org/10.1016/S0140-6736\(99\)04093-3](https://doi.org/10.1016/S0140-6736(99)04093-3).
- [27] Bellissima P, Bonfante S, La Spina G, Turturici MA, Bellissima G, Tricoli D. Complicanze della febbre bottonosa [Complications of mediterranean spotted fever]. *Infez Med*. 2001 Sep;9(3):158-62. Italian. PMID: 12087217.
- [28] Ghezala HB, Feriani N. Rickettsiose invasive mortelle diagnostiquée tardivement en réanimation [Late diagnosis of fatal invasive rickettsial disease in the Intensive Care Unit]. *Pan Afr Med J*. 2016 Dec 6;25:211. French. <https://doi.org/10.11604/pamj.2016.25.211.10452>.
- [29] Ben Mansour N, Barakett N, Haggui A, Filali T, Dahmen R, Fehri W. Une myocardite aiguë compliquant une fièvre boutonneuse méditerranéenne. À propos d'un cas. *Annales de cardiologie et d'angéiologie*. Vol 63 - N° 1, P. 55-57 ; 2014. <https://doi.org/10.1016/j.ancard.2011.05.003>.
- [30] Parola P, Paddock CD, Raoult D. Tick-borne rickettsioses around the world: Emerging diseases challenging old concepts. *Clin Microbiol Rev* 2005;18:719–56. <https://doi.org/10.1128/CMR.18.4.719-756.2005>.
- [31] Estavoyer JM, Prost M, Brion JP, et al. Fièvre boutonneuse méditerranéenne avec atteinte oculaire et thrombose rétinienne. *Bull Soc Ophthalmol Fr*. 1985 ;85(9-10) :1045-8.
- [32] Spernovasilis N, Markaki L, Papadakis M, Mazonakis N. Mediterranean Spotted Fever: Current Knowledge and Recent Advances. *Trop. Med. Infect. Dis*. 2021, 6(4), 172; <https://doi.org/10.3390/tropicalmed6040172>.

- [33] Pitigoi D, Diana Olaru L, Rafila R. Mediterranean Spotted Fever in Southeastern Romania. BioMed Research International January 2013 2013(4):395806. <https://doi.org/10.1155/2013/395806>.
- [34] Bouabdellah A, DELLAL L, Moumeni M. Fièvre Boutonneuse Méditerranéenne à Tlemcen <http://dspace1.univ.tlemcen.dz/bitstream/112/10542/1>.
- [35] Botelho-Nevers E, Edouard S, Leroy Q, Raoult D. Deleterious, effect of ciprofloxacin on Rickettsia conorii-infected cells is linked to toxin-antitoxin module up-regulation. Journal of antimicrobial chemotherapy, 2012; 67(7) : 1677-1682 <https://doi.org/10.1093/jac/dks089>.
- [36] Botelho-Nevers E, Rovey C, Richet H, Raoult D. Analysis of risk factors for malignant Mediterranean spotted fever indicates that fluoroquinolone treatment has a deleterious effect. Journal of antimicrobial chemotherapy. 2011; 66(8): 1821-1830. <https://doi.org/10.1093/jac/dkr218>.